

Elliptical Excisions

Variations and the Eccentric Parallelogram

Leonard H. Goldberg, MD, FRCP; Murad Alam, MD

Background: The elliptical (fusiform) excision is a basic tool of cutaneous surgery.

Objective: To assess the design, functionality, ease of construction, and aesthetic outcomes of the ellipse.

Design: A systematic review of elliptical designs and their site-specific benefits and limitations. In particular, we consider the (1) context of prevailing relaxed skin tension lines and tissue laxity; and (2) removal of the smallest possible amount of tissue around the lesion and in the “dog-ears.” Attention is focused on

intuitive methods that can be reproducibly planned and executed.

Results: Elliptical variations are easily designed and can be adapted to many situations. The eccentric parallelogram excision is offered as a new technique that minimizes notching and focal tension in the center of an elliptical closure.

Conclusion: The elliptical (fusiform) excision is an efficient, elegant, and versatile technique that will remain a mainstay of the cutaneous surgical armamentarium.

Arch Dermatol. 2004;140:176-180

THE PRIMARY LINEAR CLOSURE of an elliptical excision is a crucial tool in cutaneous reconstruction.¹ Although the excision is more properly called *fusiform* than *elliptical* because its edges are pointed not rounded,²⁻⁴ such a closure provides excellent cosmesis by minimizing tissue removal, skin movement, and incision length. Simplicity and versatility are among the other benefits.⁵ The side-to-side closure is easily learned by beginners and, in skilled hands, can be precisely everted and camouflaged within skin tension lines so as to be barely visible after healing. Variations in the basic technique of the elliptical excision can be used to adapt it to the particular circumstances facing the surgeon. Case-specific technique refinements can increase the reliability of the elliptical design, while accommodating specific anatomical topography.

The classic ellipse is formed by tracing 2 arcs of a circle on the skin (**Figure 1**). The arcs, which are symmetrical with respect to the midline axis separating them, intersect at their ends to form a convex shape. Commonly used curvature is variable, but typically leads to a 1:3 to 1:4 width-length ratio between the short and

long axes of the formed ellipse, which is more correctly described as fusiform given the sharp edges. Although an elliptical angle of 30° has been traditionally assumed at the ends (intersection of the arcs), it has been shown that in practice this is likely closer to 50°.⁶ The arciform elliptical excision, although conceptually elegant, is difficult to construct. It is challenging for the surgeon to maintain an even rate of curvature while wielding a scalpel, and the resulting arcs are frequently uneven. Also, the 90° angle between the blade and the skin that is optimal for closure may be lost as the surgeon concentrates on turning the blade steadily.

A more easily executed variant of the arciform ellipse is the tangent-to-circle (rhombic) excision (**Figure 2** and **Figure 3**), which entails edge angles closer to 30°. With this technique, the surgeon incises straight lines radiating in opposite directions from the 2 ends of a diameter, bisecting the circle that represents the defect. The 2 sets of tangent lines each touch the edge of the defect at a single point and then proceed laterally to a point 1.5 to 2 diameters away, where they intersect and terminate. Intuitively, 2 triangular segments engulf the defect and collectively form a diamond-shaped excision.

From *DermSurgery Associates and The University of Texas M. D. Anderson Cancer Center, Houston, Tex (Dr Goldberg); and the Section of Cutaneous and Aesthetic Surgery, Department of Dermatology, Feinberg School of Medicine, Northwestern University, Chicago, Ill (Dr Alam)*. The authors have no relevant financial interest in this article.

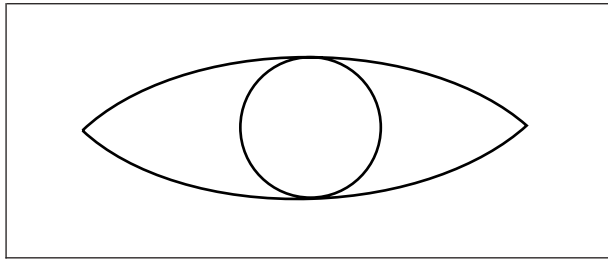


Figure 1. A classic ellipse with a 1:3 width-length ratio.

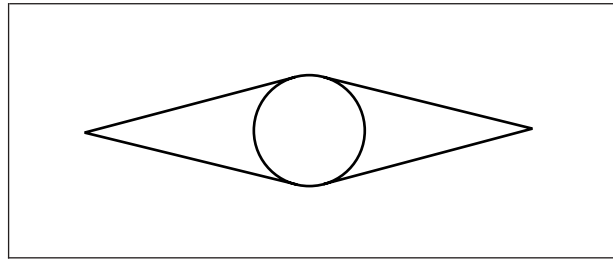


Figure 3. Tangent-to-circle, or rhombic, excision with a 1:4 width-length ratio.

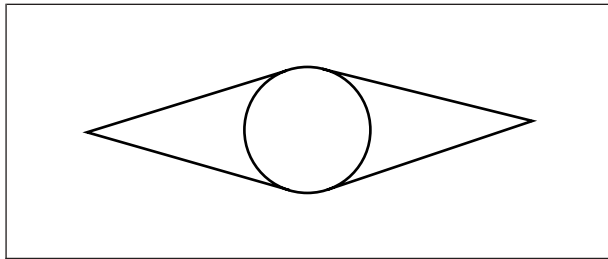


Figure 2. Tangent-to-circle, or rhombic, excision with a 1:3 width-length ratio.

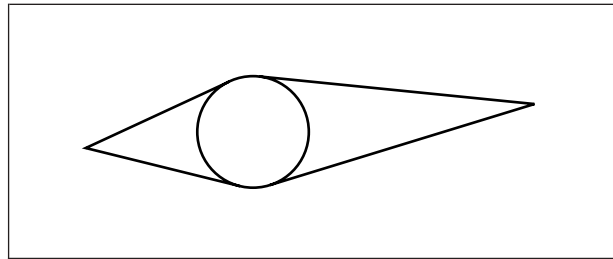


Figure 4. In a modified tangent-to-circle excision, greater skin redundancy on one side of the defect may require a larger, longer dog-ear.

The tangent-to-circle method is easier for the surgeon because of the facility with which straight lines can be cut. Four simple, quick, well-controlled motions are sufficient for definition of the diamond shape. The evenness of these lines compared with arcs ensures that “dog-ears” on either side of the defect will be even in size and taper uniformly. Less excess normal tissue is removed with straight-line dog-ears.

In some cases, it will not be desirable to have dog-ears of equal size and shape. For instance, there may be a rhytid conferring greater skin laxity on one side of the defect, and in order to place the suture line within the rhytid, a larger dog-ear may be required on that side. This step can be simply accomplished by cutting a larger triangle on one side of the defect (**Figure 4**). Alternatively, the dog-ears may need to be asymmetrical if the lines of minimal skin tension curve in the vicinity of the excision or if there is an anatomical landmark that must be avoided. Rather than lying along a diameter of the defect and forming a 180° angle, the 2 triangular segments may form a more acute angle. At times, this angle may approach 90° (**Figure 5** and **Figure 6**). Gentle curvature of skin tension lines at the defect suggests modification of the excision so that there are 2 lines along one side of the long axis and a straight line tangent to the circle on the other side (**Figure 7** and **Figure 8**). Suturing of the excision will then naturally pull the tissue along the straight margin into the corner on the contralateral side.

One problem with the rhombic (tangent-to-circle) approach is the notching that may appear at the defect midpoint. (The tangent-to-circle closure seems to have some similarities to the rhombic flap; ie, the closure of a rhombic defect by a rhombic flap may involve a side-to-side closure in the part of the defect that is not closed by the flap.) Where the angles formed by the 2 sets of lines face each other, there is the widest separation between the wound edges, and this separation manifests as a gap.

The gap is difficult to close without placing excessive tension on the suture line. One alternative design that can facilitate closure at this point entails shifting the apexes of the V-shaped indentations so that they do not abut. An eccentric parallelogram, or eccentric tangent-to-circle excision, permits each indentation to be sewn to a linear portion of the contralateral side (**Figure 9**). A large potential gap is thus divided into 2 gaps of smaller size that are more easily sutured shut. The eccentric excision can be constructed by drawing the smallest square that completely contains a circular defect and has sides parallel and perpendicular to the prevailing lines of relaxed skin tension. Lines can be extended from the corners of each side of the square parallel to skin tension lines. On each side, these lines can meet at a point, and the resulting triangular dog-ears would resemble those in the classic tangent-to-circle method (**Figure 10**). Once a surgeon has become expert at this modified technique, the eccentric parallelogram can be drawn differently, with the indentations closer to each other than with the square-based approach (**Figure 11**). Notably, the final suture line from an eccentric parallelogram closure will be S-shaped rather than linear. Relative straightness will characterize the distal arms of the S. Middle arm length will be determined by the distance between the contralateral V-shaped indentations, and the angle between the middle and distal arms by the angle at the V-shaped indentations. Zitelli⁷ and others have noted potential benefits of the S-plasty, which may minimize scar depression in convex surfaces. A variant of the eccentric parallelogram can also yield a straight final suture line. Specifically, if dog-ears shaped like isosceles triangles are removed from each side of the square encasing the circular defect, a linear closure that still limits central notching and tension can be obtained (**Figure 12**).

The degree of curvature of suture lines is, of course, contingent on more than the shape of the inci-

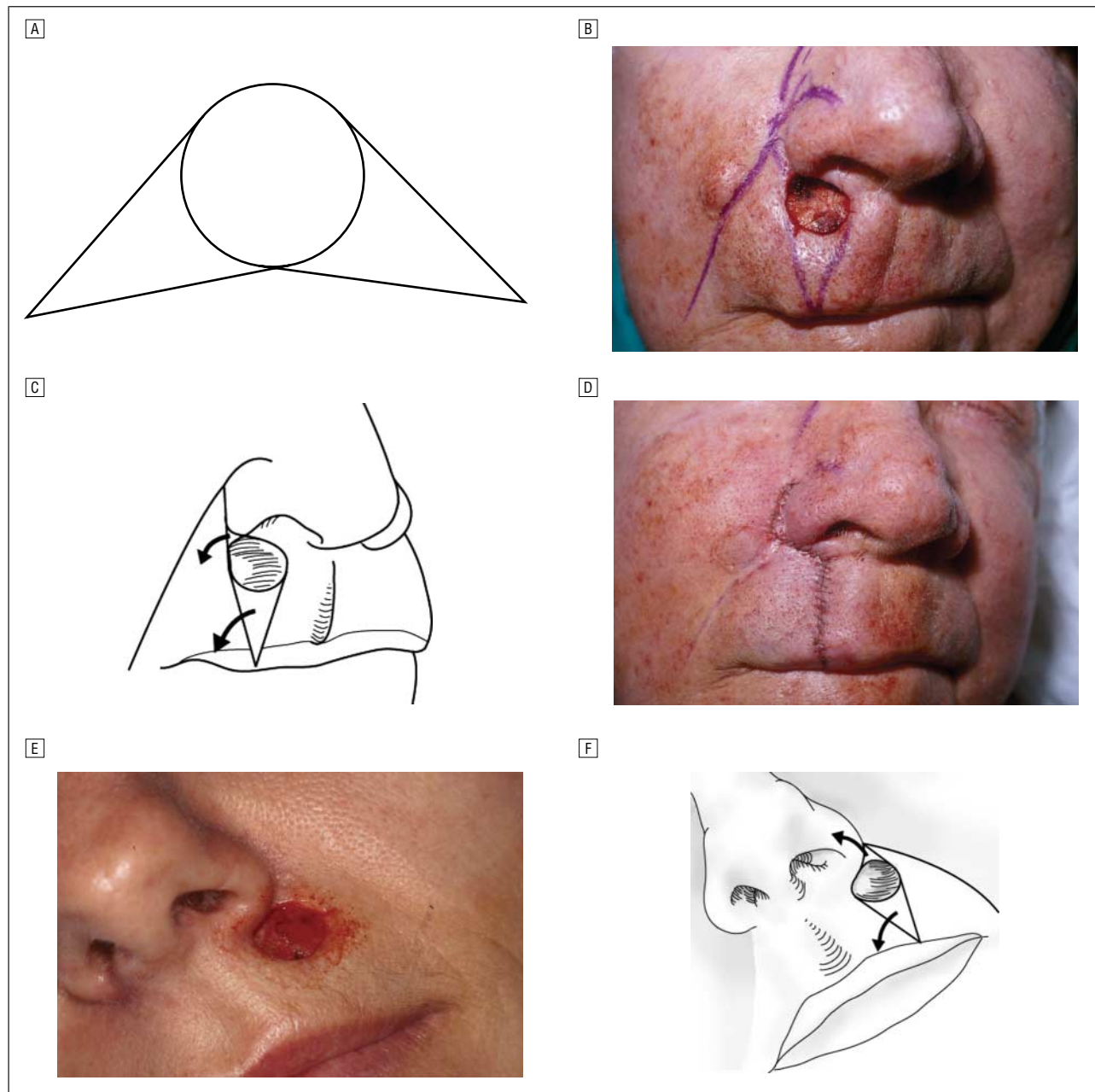


Figure 5. The dog-ears of a tangent-to-circle type of excision may be rotated toward each other to lie within skin tension lines or to avoid anatomical landmarks. The angle between the dog-ears may be somewhat less than 180° (A). An ellipse with an angle of slightly less than 180° between the dog-ears, and with a longer dog-ear on one side (as shown in Figure 4), may be better able to conform around the junction of the alar crease and lip. This can be seen in the clinical examples, including that of a male patient with a preoperative defect under the right ala (B) that required a modified ellipse (C) to repair (D) and a female patient with a similar defect under the left ala (E), which was repaired with a similar approach (F).

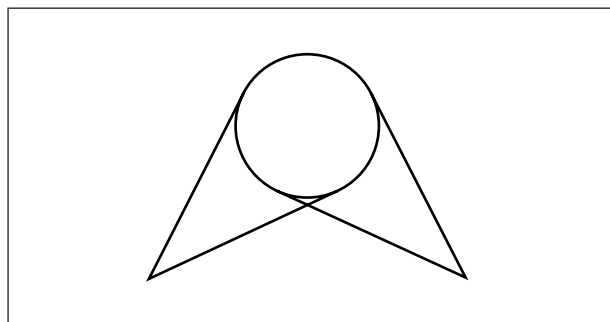


Figure 6. The angle between the dog-ears may be as small as 90° .

sion. Differential sewing techniques can exaggerate or reduce the basic degree of curvature predicated by cutting the repair. By sewing a point on one side, not to the corresponding point on the other side but rather to a point downstream or upstream, the suture line can be curved inward or outward (**Figure 13**). In expert hands, this technique can be used to create a significant kink in a straight-cut excision. Intuitive understanding of this process, which comes from experience, can facilitate the fine-tuning of a closure; ie, while careful thought should precede cutting of the excision, problems that become evident when suturing is underway

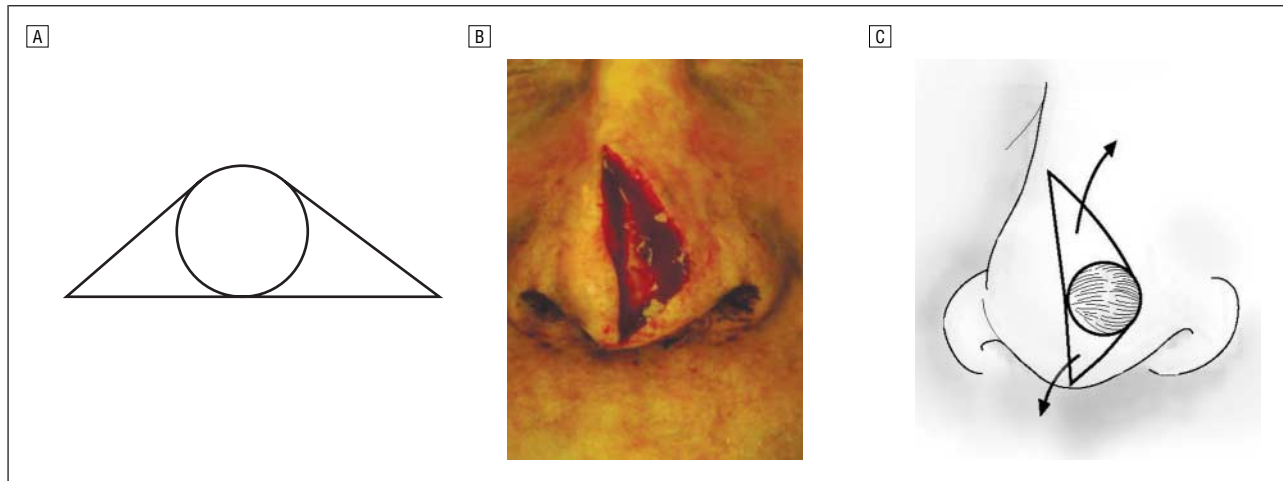

Figure 7. To camouflage an excision within smoothly curving skin tension lines, the tangent-to-circle method can be modified so that a straight line is cut along one side of the defect (A). A clinical example would be an off-center defect on the dorsal surface of the lower nose area (B), where a straight line along one side of the ellipse would appropriately orient the lower dog-ear in the midline of the columella, while creating an overall curvature of the final closure (C).

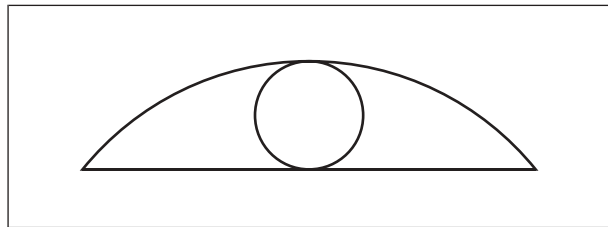


Figure 8. A similar variation of the classic ellipse is also possible.

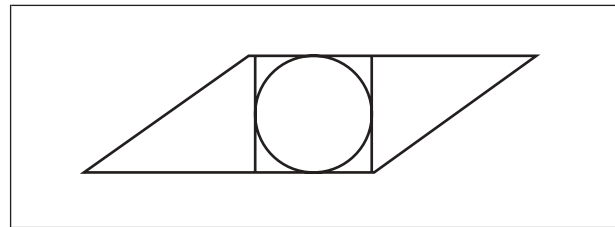


Figure 10. An eccentric parallelogram can be drawn by first encasing the defect in a square and then adding dog-ears parallel to skin tension lines.

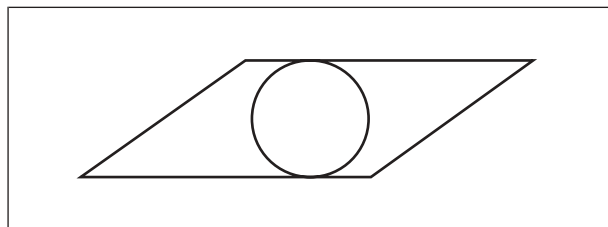


Figure 9. In an eccentric parallelogram, the 4 lines marking the boundaries are 2 different lengths. The defect is off center with respect to the central apexes of the excision, and each such notch is sewn to a linear portion of the opposing wound edge.

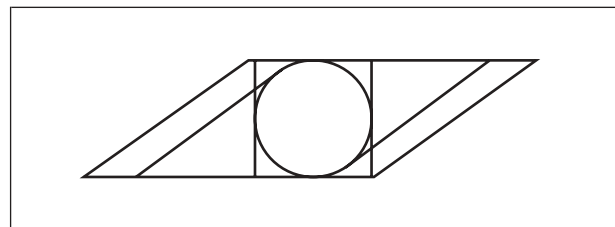


Figure 11. The eccentric parallelogram can be barely eccentric, as in the case of the standard tangent-to-circle excision described by the inner set of lines, or more eccentric as denoted by the outer set of lines.

can be corrected by differential sewing of the sides. Specifically, such shape modification may permit better recession within skin lines or more aesthetically pleasing avoidance of anatomical landmarks.

The tangent-to-circle method and the eccentric parallelogram variant can also be adapted to excisions where a margin of safety is removed around the final defect. First, the size of the margin must be determined. Then, the tangent-to-circle can be drawn starting with this amount of space separating the defect and excision walls at the previous point of tangency between the edges of the circular defect and the cut lines (**Figure 14**). Similarly, in the eccentric parallelogram, an equivalent distance can be left between the defect and the encasing square (**Figure 15**). In both cases, once the point of origin of the lines is determined, the rest of the procedure is carried out as described above.

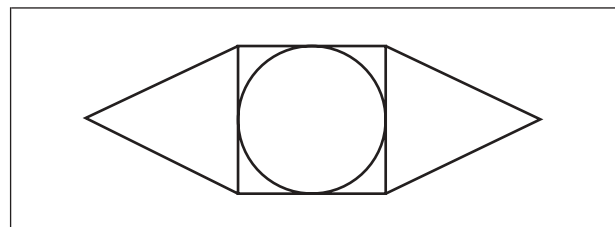


Figure 12. A linear closure based on the concept of the eccentric parallelogram is shown. Dog-ears shaped like isosceles triangles are added to each side, and the central notching associated with a standard tangent-to-circle closure is avoided.

In summary, the elliptical excision remains an adaptable and essential surgical strategy. When adequate tissue is present for a primary closure, a variant of the tangent-to-circle approach will usually be sufficient to orient the suture line within relaxed tension lines and ensure that appropriate-sized dog-ears are removed. The

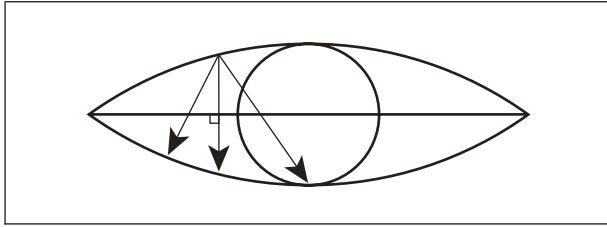


Figure 13. Sewing points on one side of the excision to corresponding points on the other side (connected by a line perpendicular to the long axis bisector) results in a linear closure. Connecting a point to a point preceding or following the corresponding point on the other wound edge can result in inward or outward curvature of the suture line.

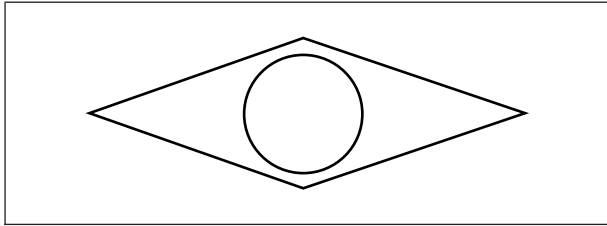


Figure 14. A minimum margin can be left between the edge of a circular defect and the tangent-to-circle lines drawn around it. This can be conceptualized as a tangent-to-circle design that is tangent to an invisible concentric circle of somewhat greater diameter.

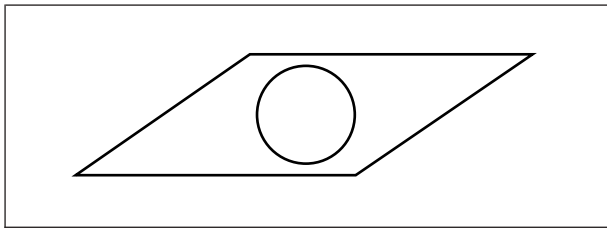


Figure 15. An eccentric parallelogram with a minimum margin around the central defect is shown.

eccentric parallelogram can minimize notching at the closure midpoint by distributing central tension over a wider interval.

While these approaches can facilitate construction of elliptical excisions, surgical ellipses are inherently forgiving and tend to culminate in cosmetically acceptable scars even if the operative technique is less than ideal. As trainers of novice surgeons are aware, the inability to maintain a perfect and even rate of curvature, or to adhere to other geometric strategies for lesion removal, does not preclude a good outcome. At the same time, precise planning of excisions based on awareness of specific defect characteristics and local anatomical features can only enhance the likelihood of an optimal result.

Accepted for publication June 25, 2003.

The illustrations for this article were drawn by Maya Goldberg, BS, BA.

Corresponding author: Murad Alam, MD, Dermatology, 675 N Saint Clair, Suite 19-150, Chicago, IL 60611 (e-mail: murad@alam.com).

REFERENCES

1. Dunlavy E, Leshin B. The simple excision. *Dermatol Clin*. 1998;16:49-64.
2. Goldberg LH. Cold steel surgery: the ellipse. In: Lask GP, Moy RL, eds. *Principles and Techniques of Cutaneous Surgery*. New York, NY: McGraw-Hill Co; 1996:165-170.
3. Alam M, Goldberg LH, Berkes B. Basic excisional surgery. In: James WD, Elston D, eds. *eMedicine Dermatology*. St Petersburg, Fla: eMedicine Corp; 2002.
4. Buntine JA. "Elliptical" excision and suture. *Med J Aust*. 1969;2:449-450.
5. Pardasani AG, Leshin B, Hallman JR, White WL. Fusiform incisional biopsy for pigmented skin lesions. *Dermatol Surg*. 2000;26:622-624.
6. Moody BR, McCarthy JE, Sengelmann RD. The apical angle: a mathematical analysis of the ellipse. *Dermatol Surg*. 2001;27:61-63.
7. Zitelli JA. TIPS for a better ellipse. *J Am Acad Dermatol*. 1990;22:101-103.